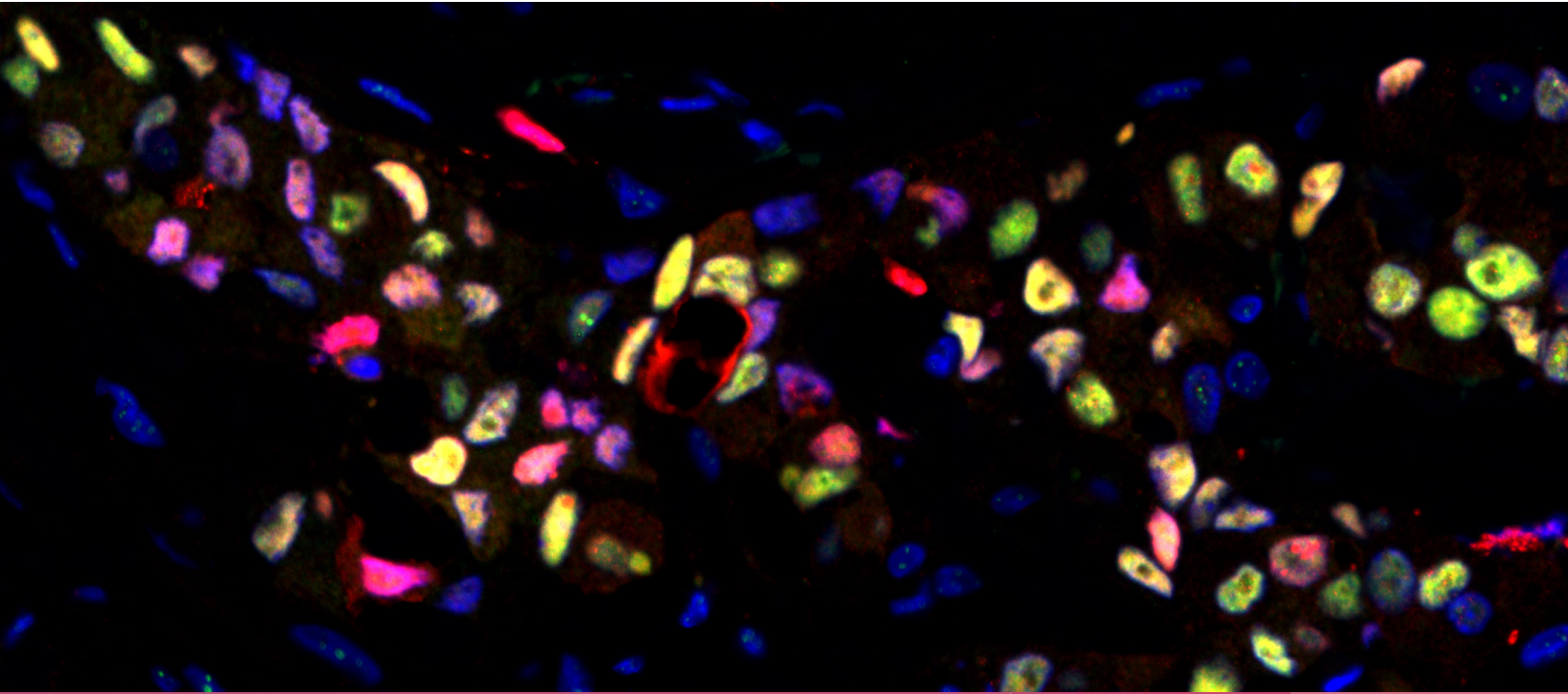

ENDOCRINE- RELATED CANCER

**HORMONES AND CANCER:
FROM RESEARCH TO THERAPIES**

CONTEMPORARY PERSPECTIVES IN HORMONE-DEPENDENT CANCERS



published by
bioscientifica

AN OFFICIAL
ESE
JOURNAL

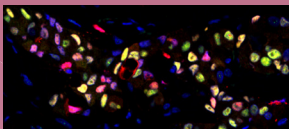
The Society for Endocrinology is one of the world's leading authorities on hormones.

Established in 1946, the Society's aims are to support the advancement of scientific and clinical knowledge and increase research in endocrinology for the public benefit. It also plays a vital role in promoting and supporting endocrinology worldwide.

The Society for Endocrinology offers a range of journals including *Journal of Endocrinology*, *Journal of Molecular Endocrinology*, *Endocrine-Related Cancer*, *Endocrine Connections* (open access) and *Clinical Endocrinology*.

For more information visit www.endocrinology.org

COVER ART COMPETITION



Readers are invited to submit their endocrinology images for entry into the *Endocrine-Related Cancer* cover art competition. Winners will be selected by the Editor-in-Chief and will have their imagery featured on the cover of an issue of *Endocrine-Related Cancer*, both in print and online. Winners will be cited in the journal and will receive a professionally printed copy of the journal cover featuring their scientific image.

To enter the competition please email your images to erc@endocrinology.org accompanied with a short caption of 25-30 words explaining what the image depicts, its magnification and who should be acknowledged for its production. Images should be of high quality and resolution of at least 300 dpi at the final published size 220 mm (W) × 100 mm (H).

By submitting an image you warrant that you own the copyright and agree that images may be used in promotional material. Images not selected for use may still be used by the Society for Endocrinology and Bioscientifica for promotional purposes.

THIS ISSUE'S COVER

The image depicts double immunofluorescence localisation of full-length androgen receptor (AR, red) and an AR variant (ARv7, green) in a tissue section derived from an estrogen receptor-negative, progesterone receptor-negative, HER2-positive infiltrating breast carcinoma from a postmenopausal women. Most cells express detectable levels of ARv7 along with full-length AR.

Credit: G Tarulli (University of Adelaide, Australia)

